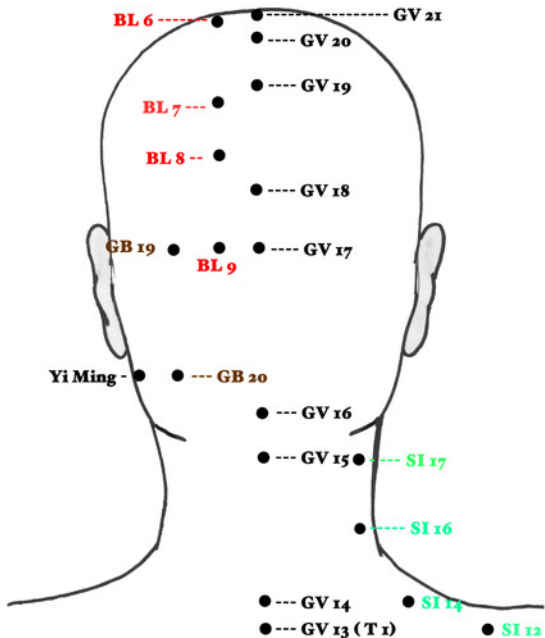
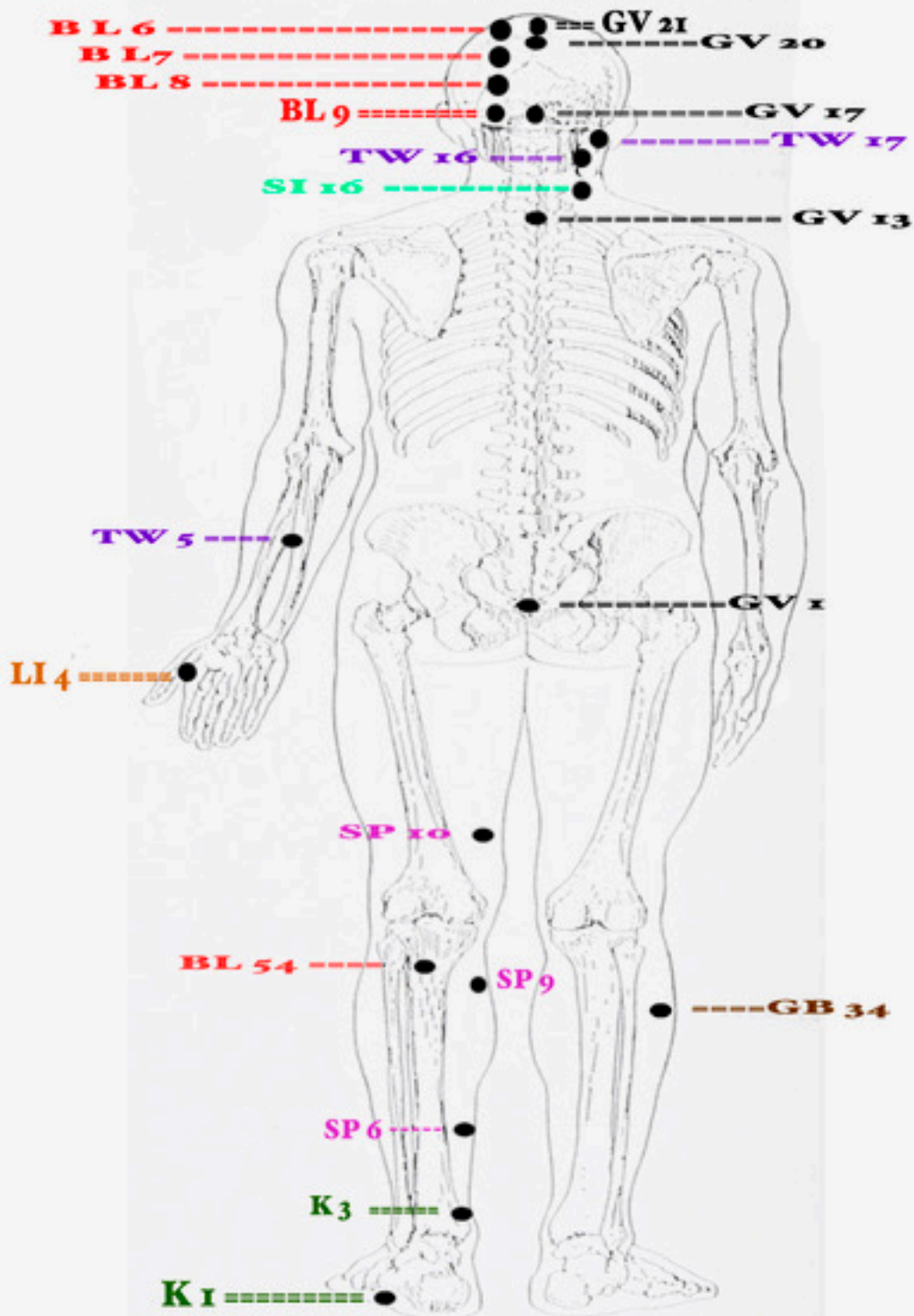


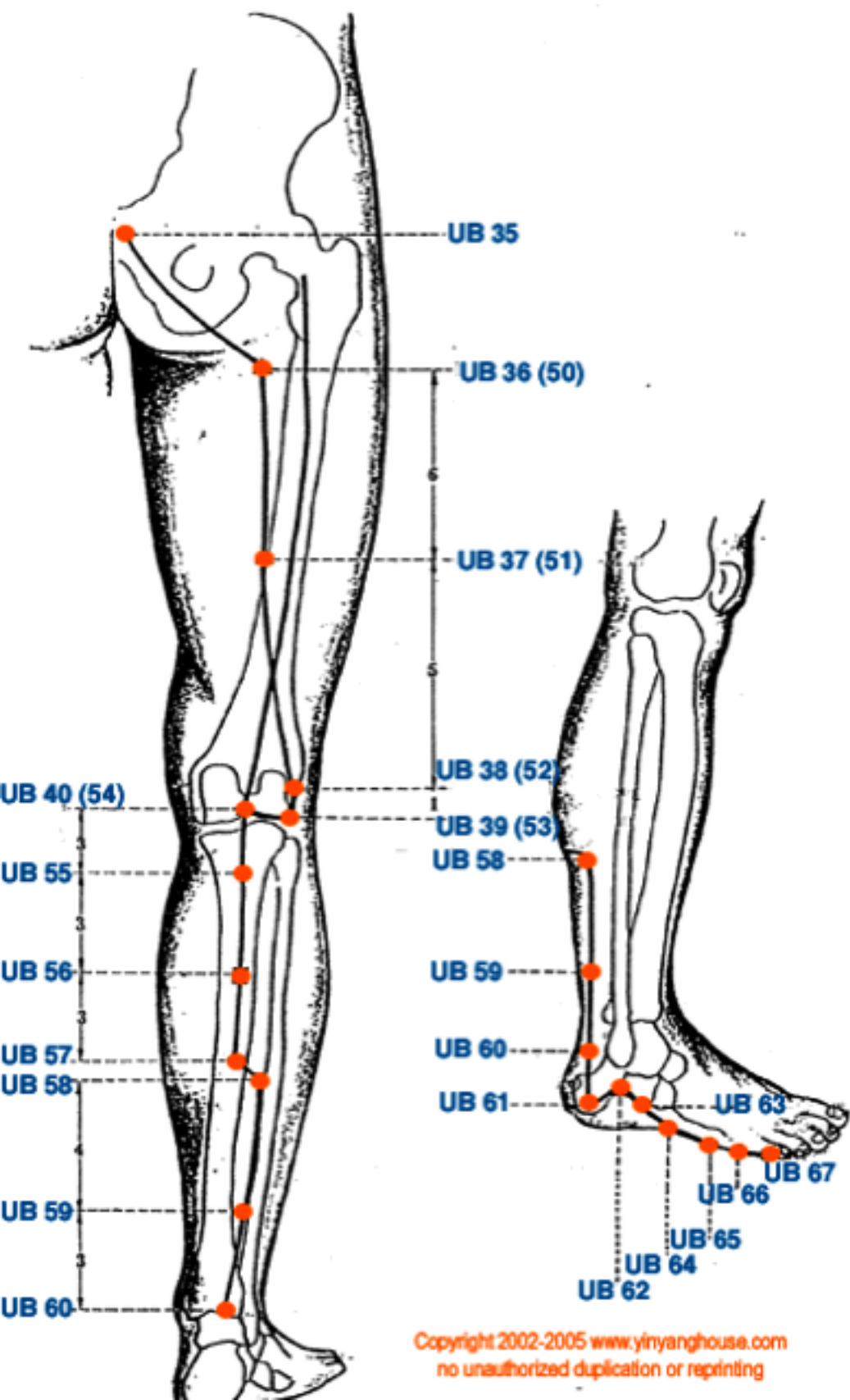
Back of Head

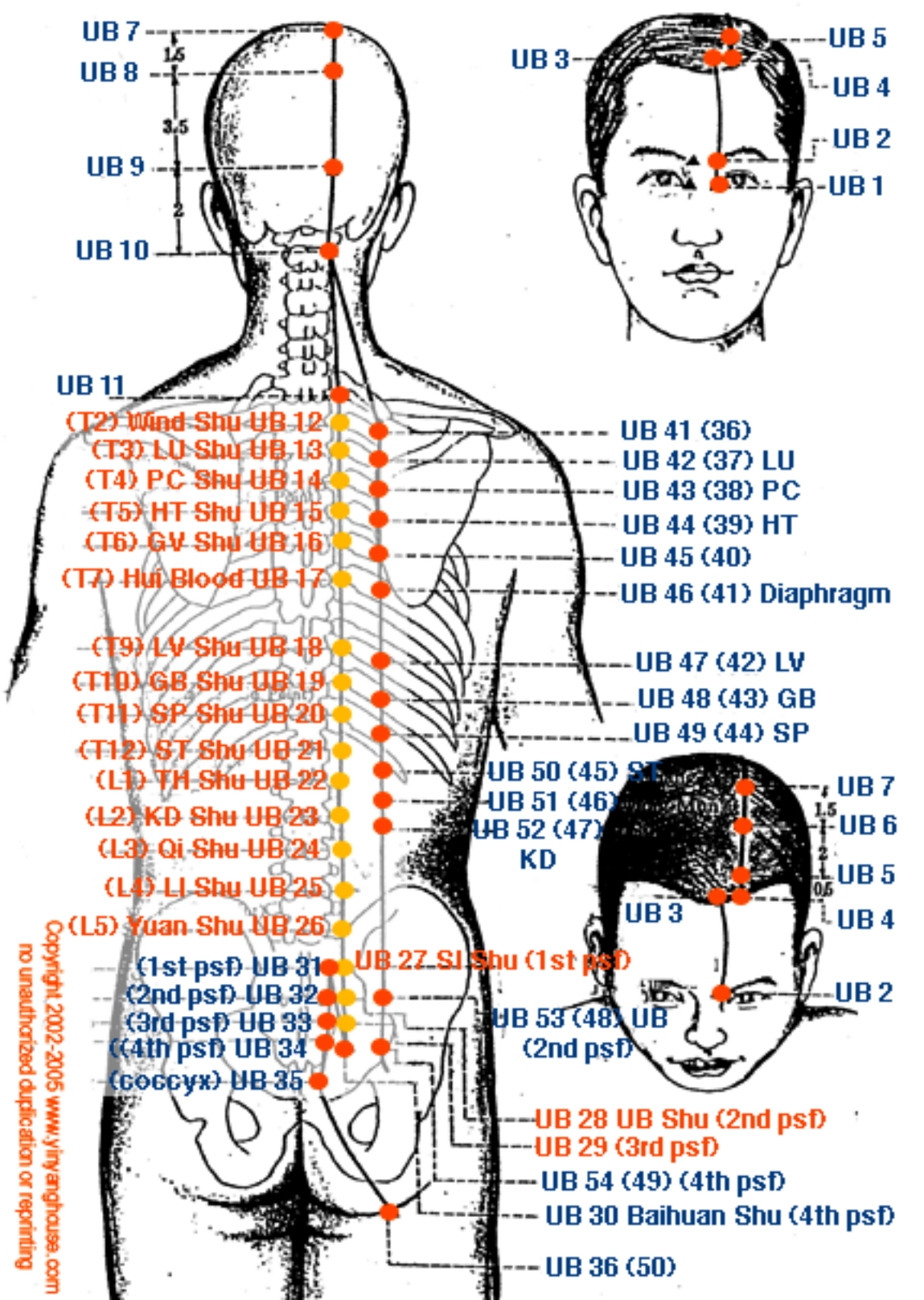


Back View of Skeleton



Mid-Sole of Foot





UB 7
 UB 8
 UB 9
 UB 10

1.5
 3.5
 2

UB 5
 UB 4
 UB 2
 UB 1

UB 11
 (T2) Wind Shu UB 12
 (T3) LU Shu UB 13
 (T4) PC Shu UB 14
 (T5) HT Shu UB 15
 (T6) GV Shu UB 16
 (T7) Hui Blood UB 17
 (T9) LV Shu UB 18
 (T10) GB Shu UB 19
 (T11) SP Shu UB 20
 (T12) ST Shu UB 21
 (L1) TH Shu UB 22
 (L2) KD Shu UB 23
 (L3) Qi Shu UB 24
 (L4) LI Shu UB 25
 (L5) Yuan Shu UB 26

UB 41 (36)
 UB 42 (37) LU
 UB 43 (38) PC
 UB 44 (39) HT
 UB 45 (40)
 UB 46 (41) Diaphragm
 UB 47 (42) LV
 UB 48 (43) GB
 UB 49 (44) SP

(1st psf) UB 31
 (2nd psf) UB 32
 (3rd psf) UB 33
 (4th psf) UB 34
 (coccyx) UB 35

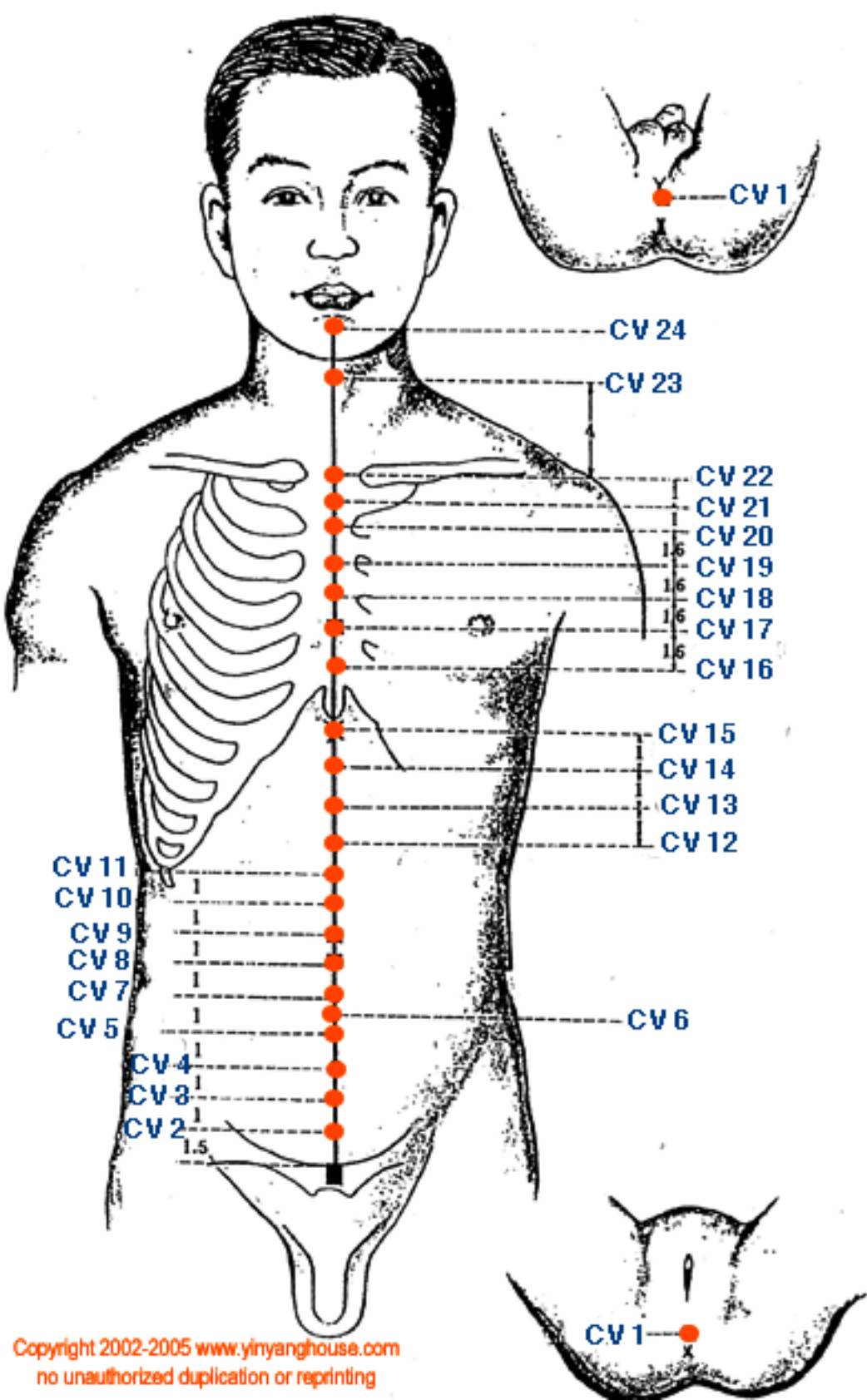
UB 7
 UB 6
 UB 5
 UB 4
 UB 3
 UB 2

1.5
 2
 0.5

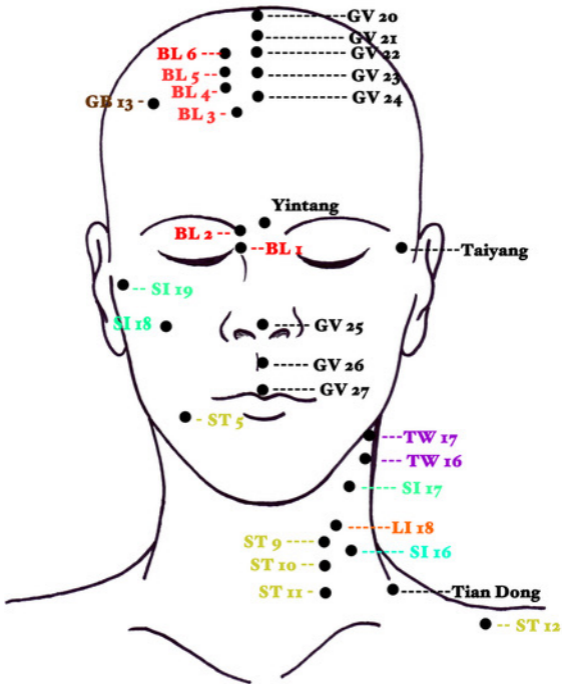
UB 50 (45) ST
 UB 51 (46)
 UB 52 (47)
 KD
 UB 53 (48) UB
 (2nd psf)

UB 27 SI Shu (1st psf)
 UB 28 UB Shu (2nd psf)
 UB 29 (3rd psf)
 UB 54 (49) (4th psf)
 UB 30 Baihuan Shu (4th psf)
 UB 36 (50)

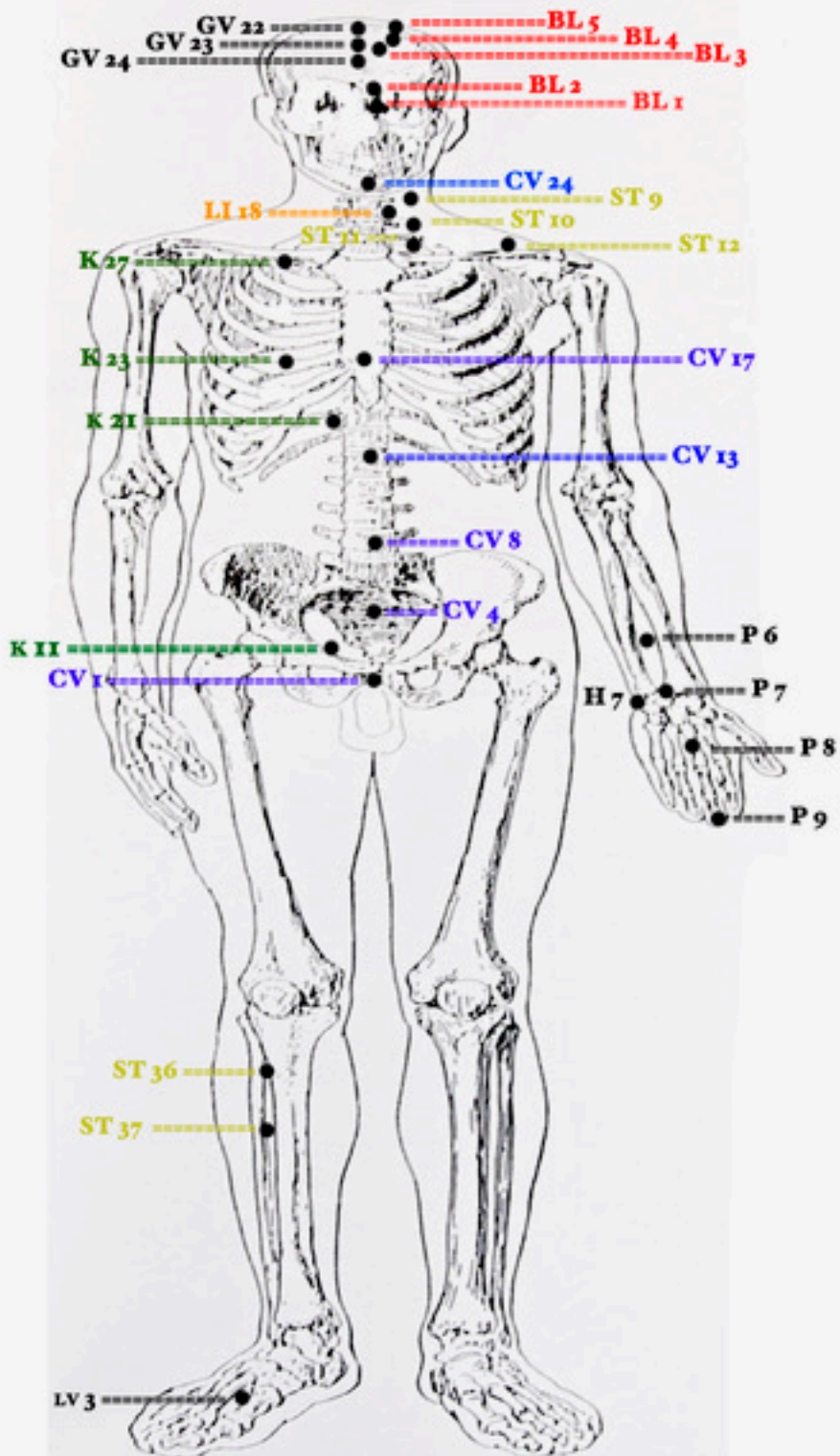
Copyright 2002-2005 www.yinyanghouse.com
 no unauthorized duplication or reprinting

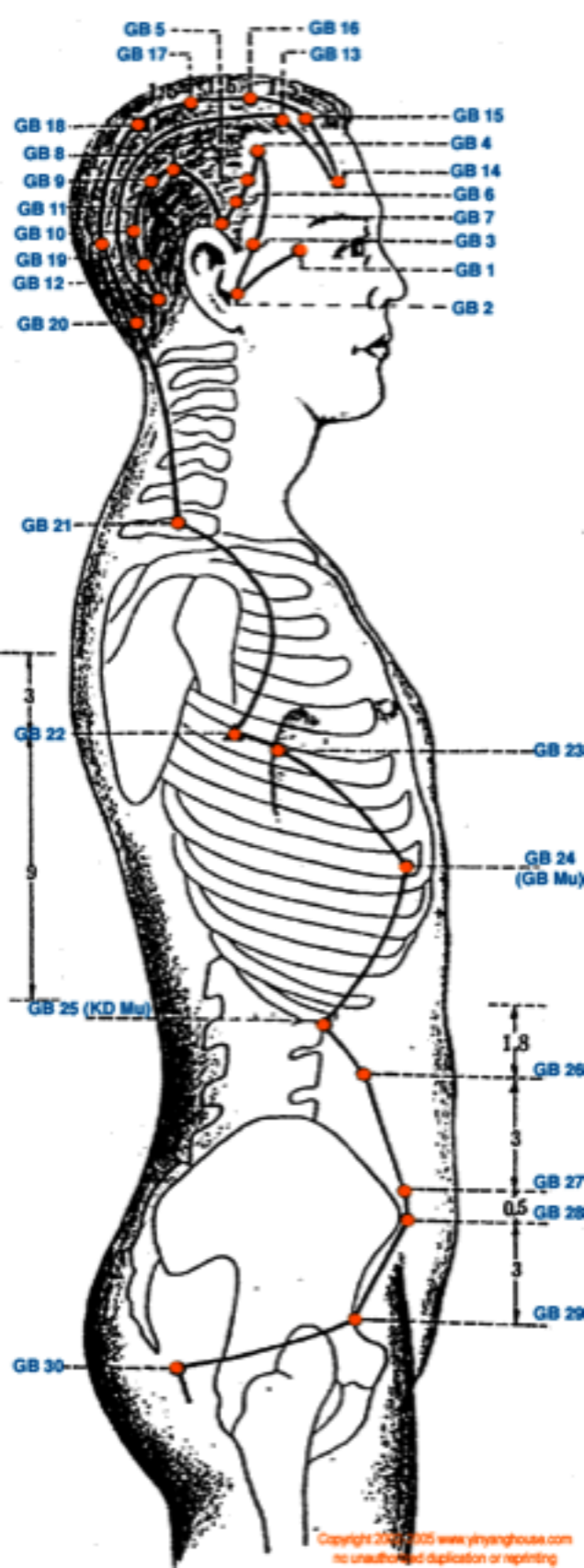


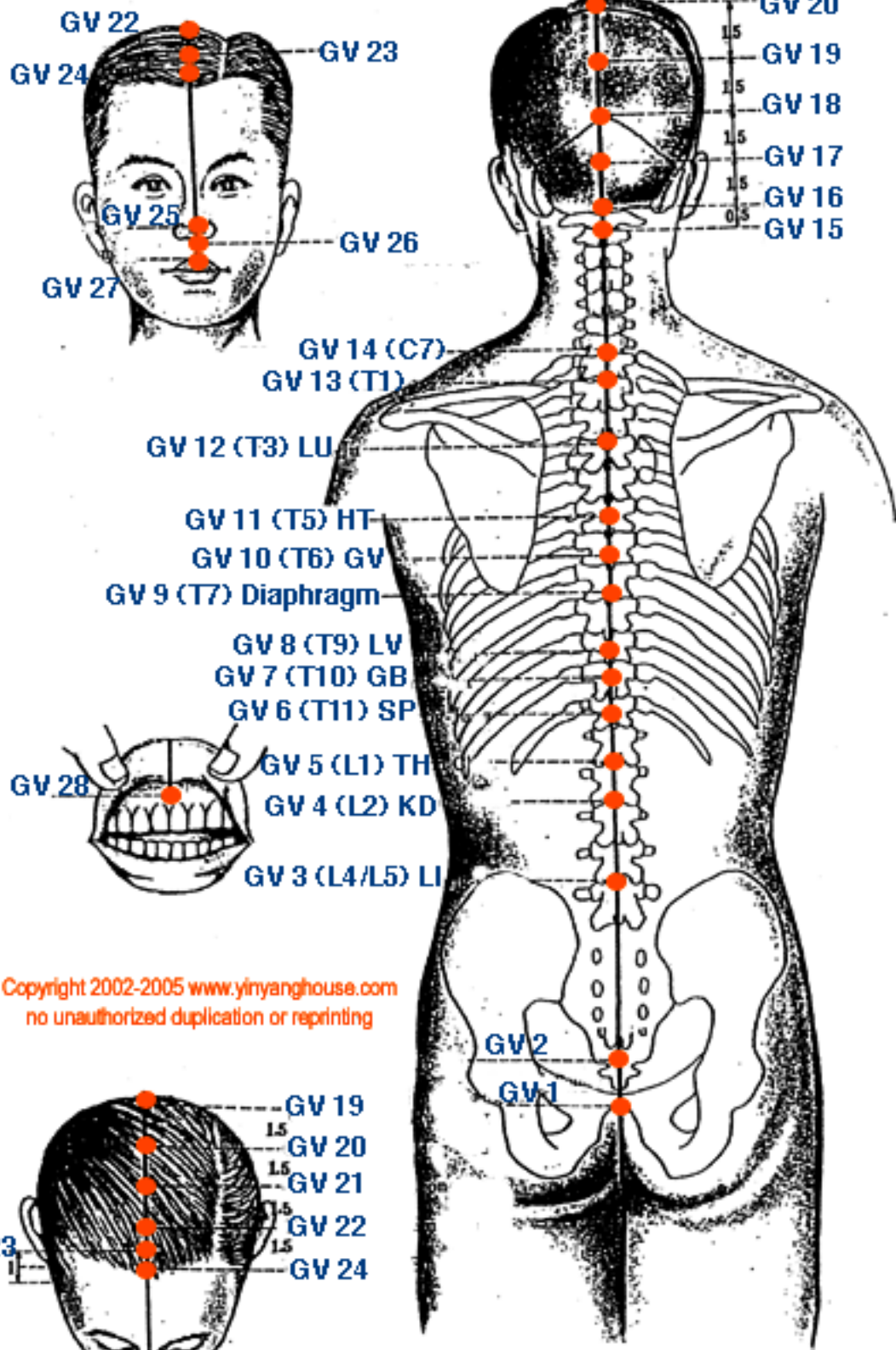
Front of Head



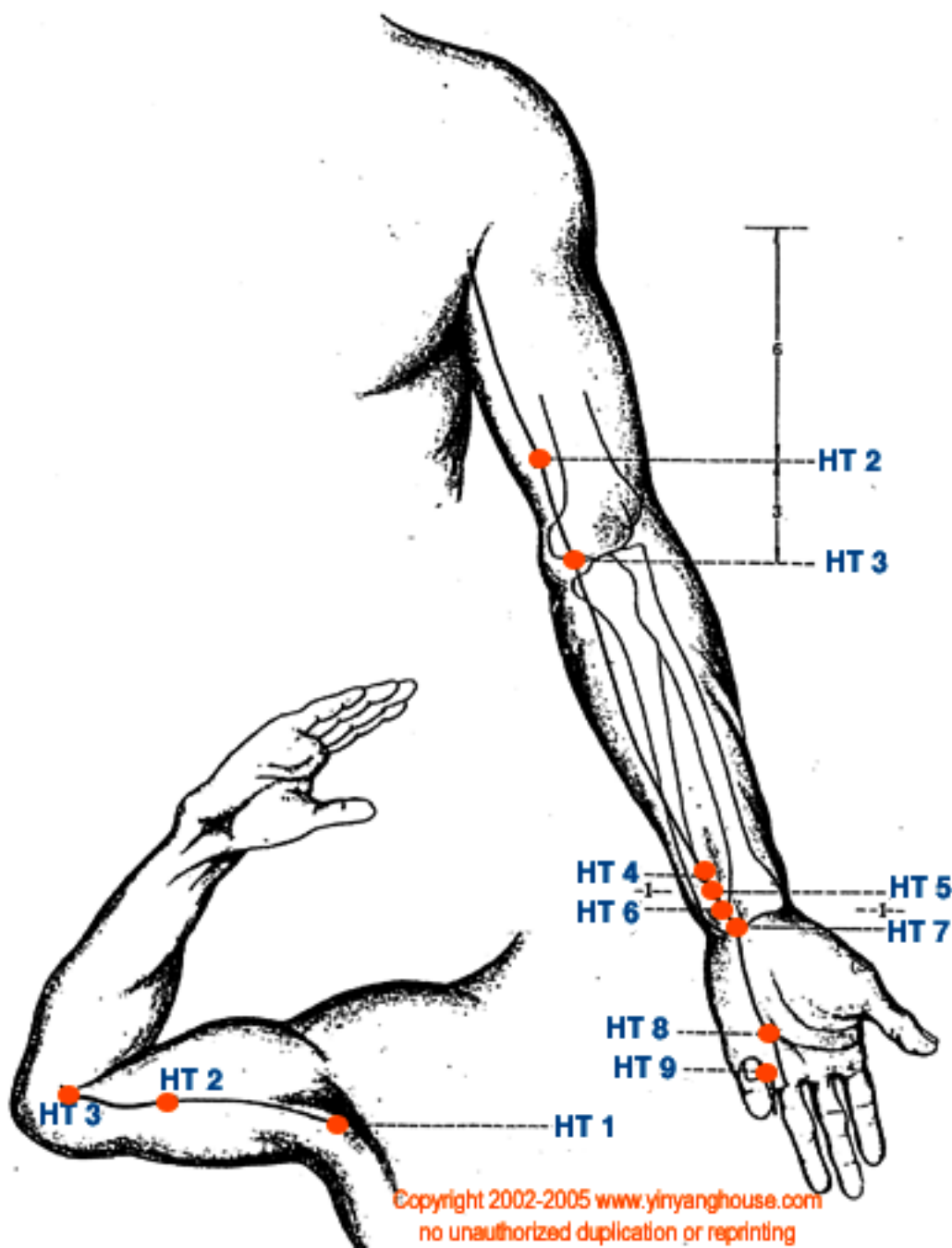
Front View of Skeleton

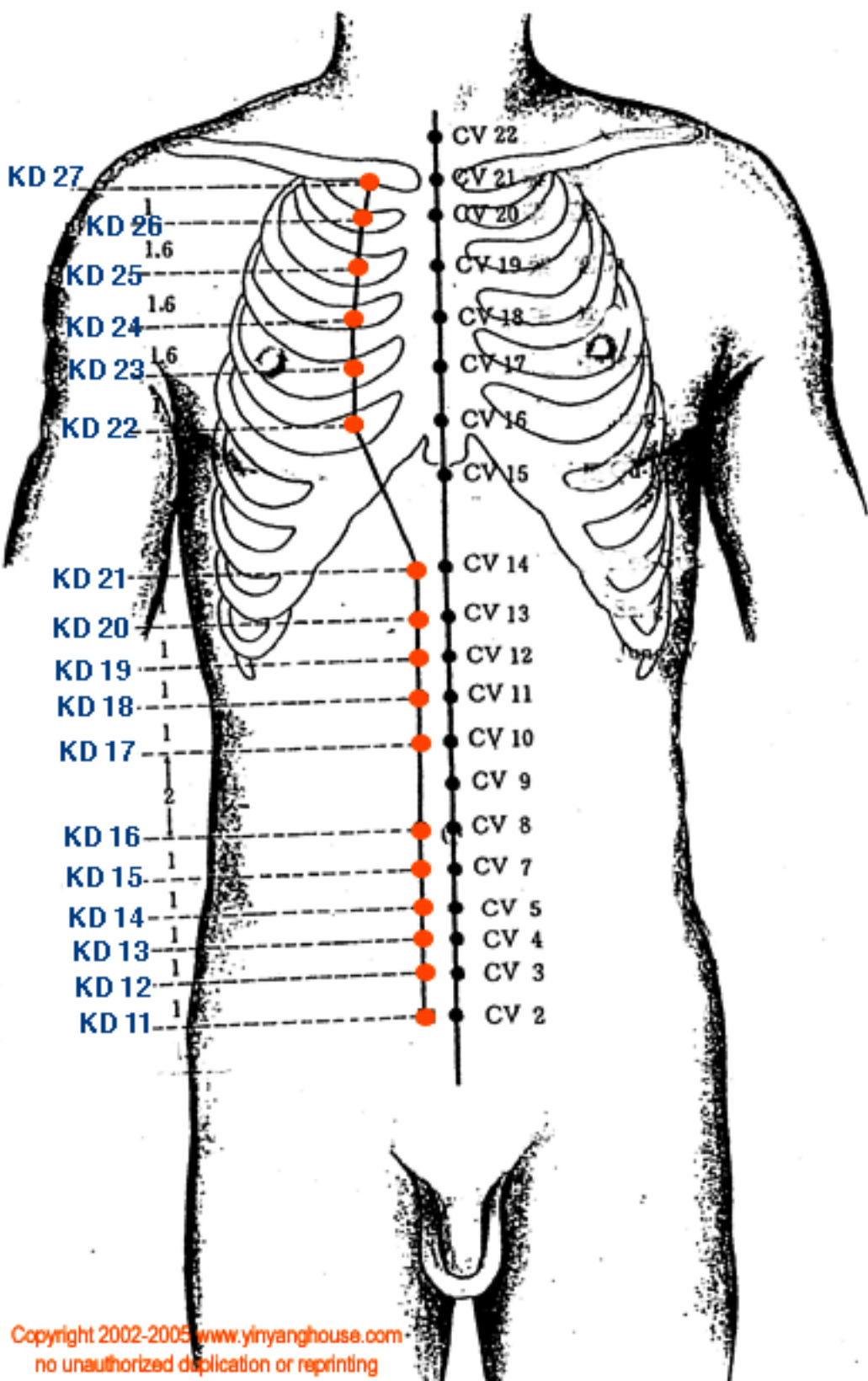


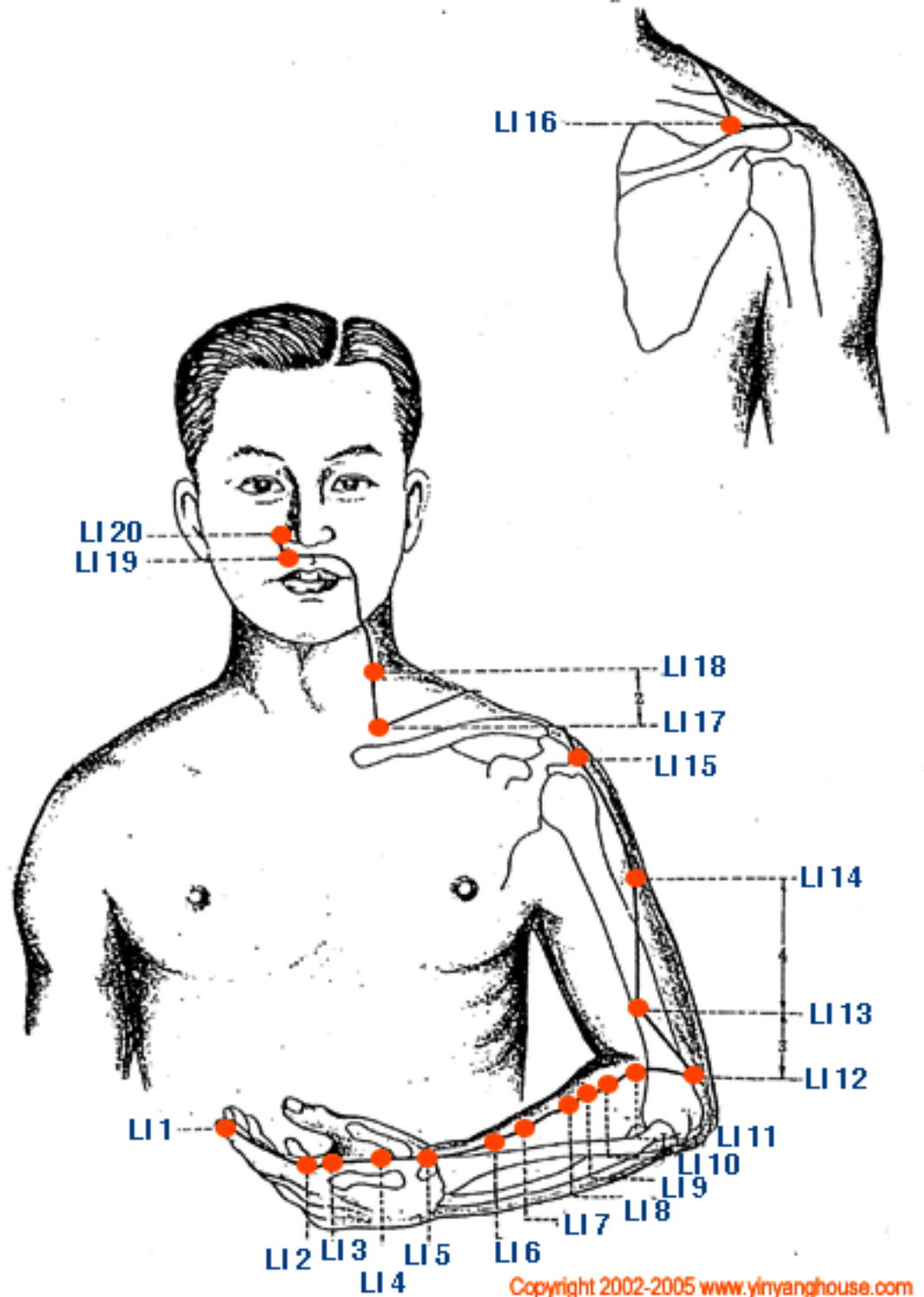


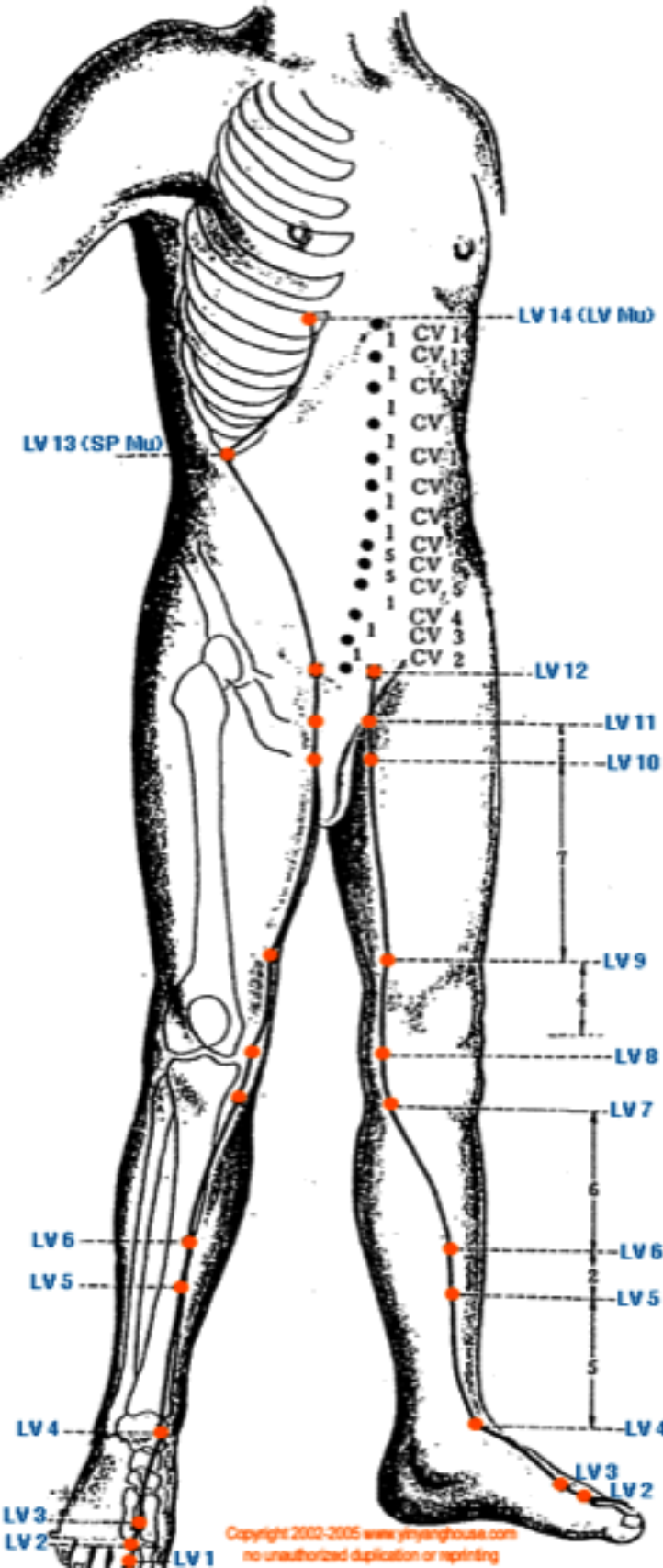


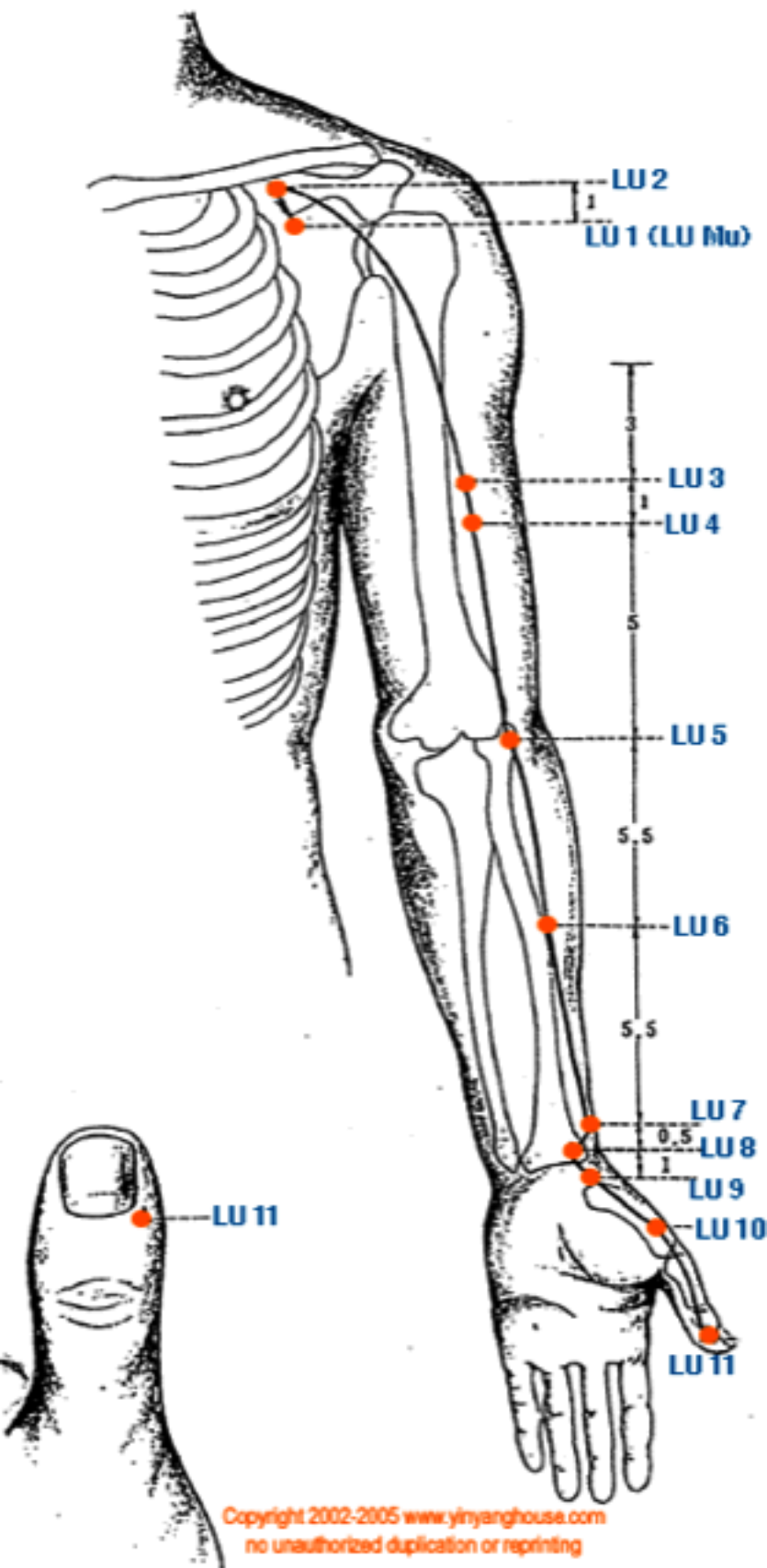
Copyright 2002-2005 www.yinyanghouse.com
 no unauthorized duplication or reprinting

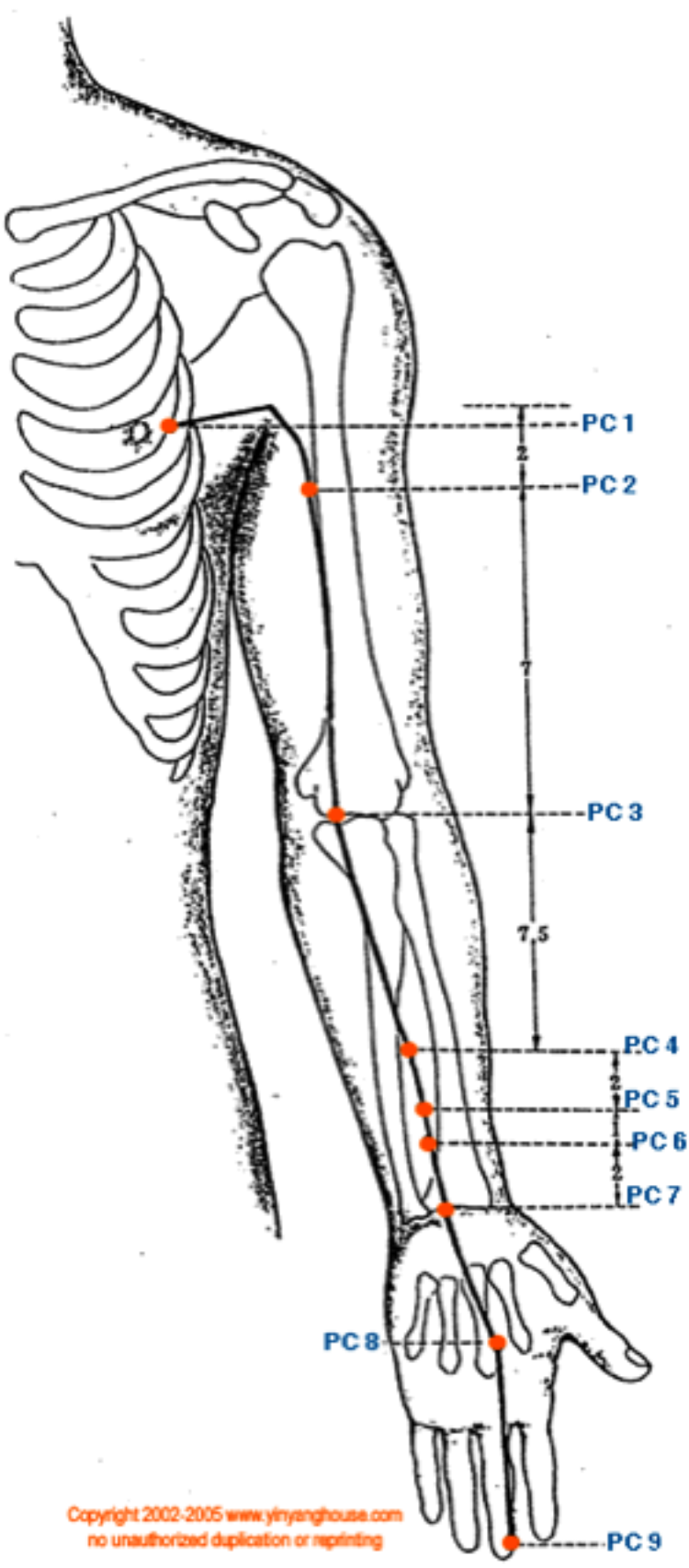


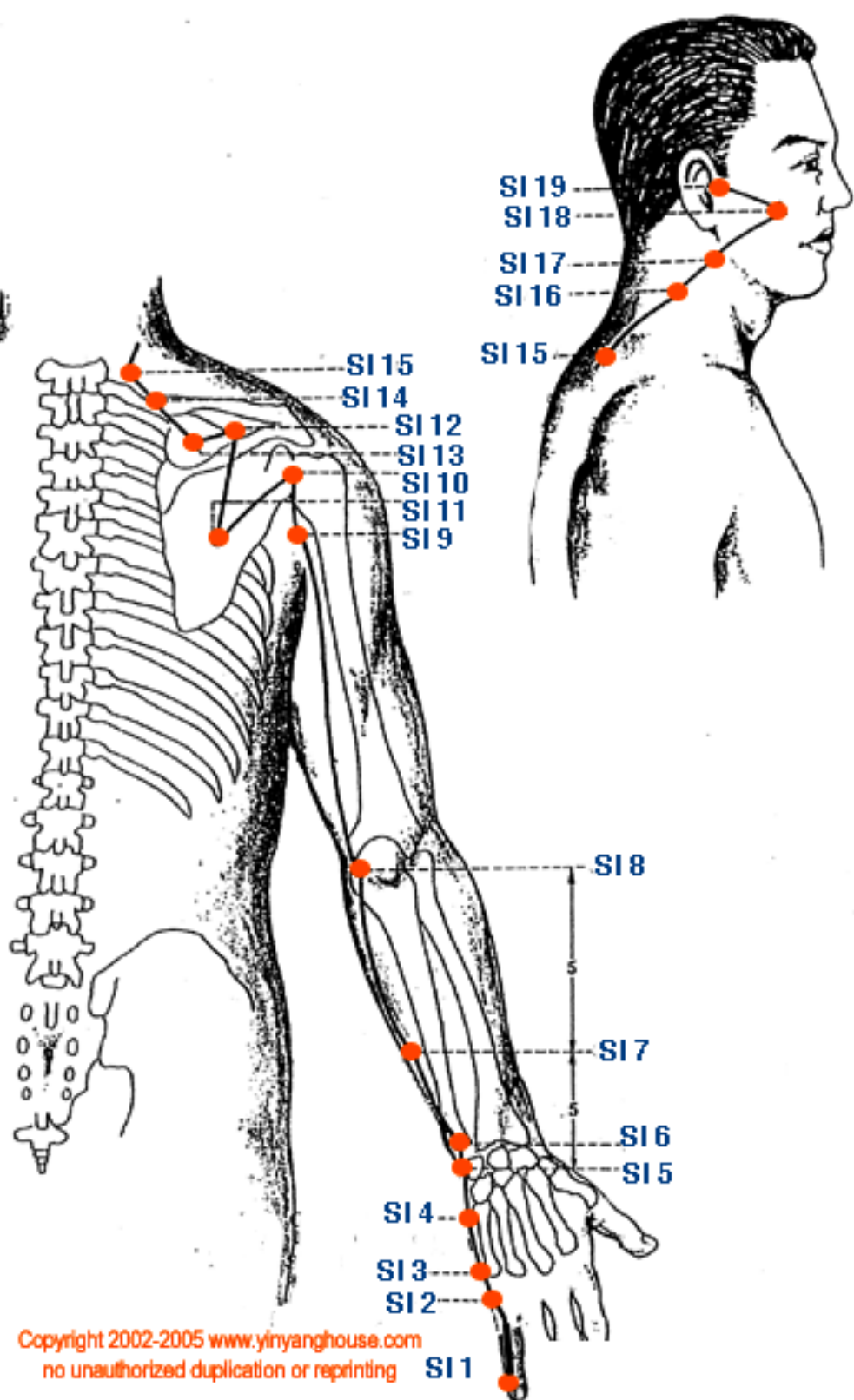












Spine

Cervical

Head, Neck, Diaphragm

Deltoids, Biceps
Triceps
Hand

Thorax

Chest Muscles

Abdominal Muscles

Lumbar

Leg Muscles

Sacrum

Bowel, Bladder
Kidney
Sexual Function

Coccyx

